

Gigantic Appendiceal Mucocele: A Case Report and Analysis of Diagnosis and Treatment

Zhanwei Wang, Pengfei Wang, Zengrong Jia, Xiuling Wu, Shaoliang Han*

Department of General Surgery, The First Affiliated Hospital of Wenzhou Medical College, Wenzhou
Email: *slhan88@yahoo.com.cn

Received: Jul. 4th, 2012; revised: Jul. 18th, 2012; accepted: Jul. 23rd, 2012

Abstract: A 63-year old female complained of right lower abdominal mass for 3 months, and she was admitted to hospital with a diagnosis colon tumor. On physical examination, an abdominal mass was found in her right quadrant, sized in 13 cm × 8 cm × 6 cm, hard, movable with clear margin. Laboratory examination revealed that Hb 12.4 g/L, CEA 5.4 μg/L, CA125 24.4 U/mL, CA153 U/mL and CA19-9 < 2.0 U/mL. A cord-like cystic mass in right abdominal cavity, primitive impression of gastrointestinal tumor, was detected by ultrasound examination, and CT scan demonstrated that a cystic occupation in right pelvic cavity, and exophytic tumor at cecum was found by fibrocolonoscopy. An exploratory laparotomy underwent by epidural anesthesia, a sausage-like tumor with size of 15 cm × 8 cm × 5 cm was seen at right abdominal cavity, and a diagnosis of appendiceal mucocele was made by intraoperative frozen pathological examination, then an appendectomy was performed, and the patient recovered smoothly after operation and discharged on the 4th operation day.

Keywords: Appendix; Mucocele; Surgery

巨大阑尾黏液囊肿：一例报道与诊疗分析

王战伟, 王鹏飞, 贾曾荣, 吴秀玲, 韩少良*

温州医学院附属第一医院普外科, 温州
Email: *slhan88@yahoo.com.cn

收稿日期: 2012年7月4日; 修回日期: 2012年7月18日; 录用日期: 2012年7月23日

摘要: 患者女, 63岁, 主诉右下腹部肿块3个月, 门诊以结肠肿物收入院。查体在右下腹部触及 13 cm × 8 cm × 6 cm 大小包块、质硬、活动、边界欠清。实验室检查: Hb 12.4 g/L、CEA 5.4 μg/L、CA125 24.4 U/mL、CA153 9.6 U/mL 及 CA19-9 < 2.0 U/mL。B超检查示下腹部条索状囊性包块(首先考虑肠道来源); 腹部CT扫描示盆腔右侧囊性占位性病变; 结肠镜检查示回盲部外压性肿物。连硬麻醉下行剖腹探查, 术中见右下腹部有一个 15 cm × 8 cm × 5 cm 腊肠样囊性肿物。术中冰冻病理组织学检查诊断为阑尾黏液囊肿。故决定行阑尾切除术, 术后第4天痊愈出院。

关键词: 阑尾; 黏液囊肿; 手术

1. 引言

女性, 63岁。主诉右下腹部肿块3个月, 伴下腹部隐痛, 门诊以结肠肿物收入院。入院体检: 一般情

况好, 腹平坦, 腹壁柔软, 右下腹部触及约 13 cm × 8 cm × 6 cm 大小包块、质硬、活动、轻压痛、无反跳痛, 边界欠清, 麦氏点无压痛。实验室检查: Hb 12.4 g/L、CEA 5.4 μg/L、CA125 24.4 U/mL、CA153 9.6 U/mL 及 CA19-9 < 2.0 U/mL。B超检查提示下腹部条索状囊

*通讯作者。

性包块(首先考虑肠道来源)(图 1(a)); 腹部 CT 扫描提示盆腔右侧囊性占位性病变(图 1(b)); 电子纤维结肠镜检查提示回盲部外压性肿物(图 1(c))。

2011 年 3 月 25 日在连续硬脊膜外阻滞麻醉下行剖腹探查, 术中见右下腹部有一个腊肠样囊性肿物, 大小 15 cm × 8 cm × 5 cm, 张力高, 近端与盲肠壁相延续, 回盲部完整, 结肠带消失于囊肿根部。术中冰冻病理组织学检查见阑尾壁略带白色、其腔内充满白色胶冻样物质, 诊断为阑尾黏液囊肿(图 1(d))。鉴于上述探查, 决定行阑尾切除术。术后病理检查报告为阑尾黏液囊肿伴囊壁肉芽肿反应(图 1(e))。患者于术后第 4 天痊愈出院, 15 个月后随访无异常。

2. 讨论

阑尾黏液囊肿是阑尾呈囊状扩张并腔内有黏液积聚的一类少见疾病。本病病因尚不清楚, 有学者认为是由阑尾近端梗阻造成, 也有认为本病是阑尾的新生肿物^[1-3]。本病在阑尾切除术中的发现率为 0.07%~0.3%^[1,2], 女性多见, 男女比例为 1:3。主要症状和体征有腹痛和腹部包块。本病诊断方法主要依靠超声检

查和 CT 扫描, 但在术前难以明确诊断。B 超表现为右下腹阑尾区边界清晰的椭圆形或囊袋状肿物, 壁薄、光滑或不光滑, 多数呈椭圆形, 腔内积满液性暗区, 内部无血流信号。CT 扫描示右侧髂窝区紧邻回盲部的囊性病灶, 呈圆形或椭圆形、或管状, 囊壁光滑, 厚薄均匀。可伴有点状、条状及弧形钙化, 边界清晰, 内容物均为均匀水样密度。本病例影像学检查符合上述表现。

本病应与下列疾病鉴别: 1) 阑尾脓肿。临床症状较典型, 压痛明显, 血白细胞计数增高。脓肿壁厚, 增强扫描可见明显环形强化, 周围呈炎性浸润改变, 肠系膜脂肪密度增高或消失。2) 右侧卵巢囊肿。多发生在子宫旁附件区, 囊壁无钙化。3) 阑尾黏液性囊腺癌。右下腹髂窝区不均质肿块, 内有囊性低密度影, 边缘不规则, 周围脂肪层模糊, 可侵犯盲肠, 增强扫描肿块呈不均质强化, 有时可见壁结节。

3. 结论

手术是治疗阑尾黏液囊肿的惟一方法, 手术方式选择应遵循 1) 如囊肿较小, 位于阑尾中部或尖端,

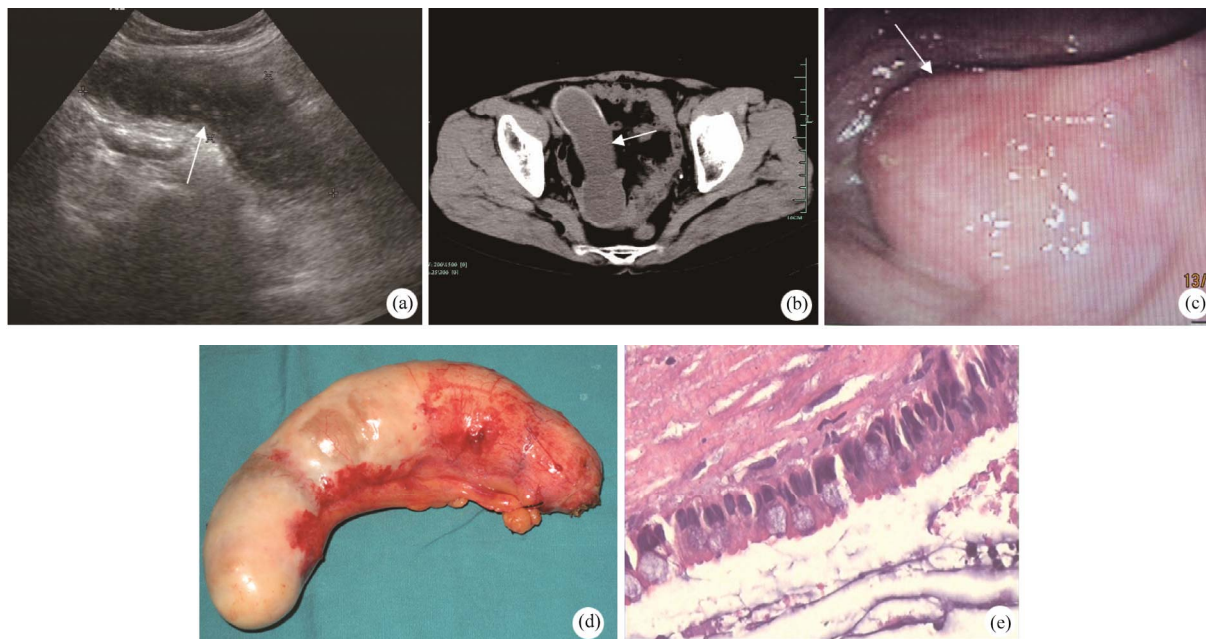


Figure 1. A cord-like cystic mass in right abdominal cavity, primitive impression of gastrointestinal tumor, was detected by ultrasound examination (a); and CT scan demonstrated that a cystic occupation in right pelvic cavity (b); and Exophytic tumor at cecum was found by fibrocolonoscopy (c); A sausage-like tumor with size of 15 cm × 8 cm × 5 cm was found at right abdominal cavity (d); The postoperative diagnosis was appendiceal mucocoele with granulomatous tissue at wall (e)

图 1. (a) B 超检查提示下腹部条索状囊性包块(箭头); (b) 腹部 CT 扫描提示盆腔右侧囊性占位性病变(箭头); (c) 电子纤维结肠镜检查提示回盲部外压性肿物(箭头); (d) 术中见一个腊肠样囊性肿物, 大小 15 cm × 8 cm × 5 cm, 张力高; (e) 术后病理检查报告为阑尾黏液囊肿伴囊壁肉芽肿反应

可行常规阑尾切除术，术后送病理检查；2) 囊肿较大，但活动性较好，粘连轻者可行回盲部切除术；3) 囊肿较大、粘连重或造成肠梗阻等并发症，应行右半结肠切除术，不应强行分离粘连，以免导致囊肿破裂，引起腹腔内种植；4) 对于术中确诊或怀疑恶变者，可行快速冰冻病理检查，如果证实为恶性肿瘤，则行根治性右半结肠切除术；5) 对于囊肿已破裂或分离时破裂，有引起腹腔假性粘液瘤的可能，必须尽量清除腹腔脏器表面黏附的胶冻物，关腹前可采用氟脲嘧啶冲

洗腹腔^[1-3]。

参考文献 (References)

- [1] J. Long, F. Yang, C. Jin, et al. Mucocele of the appendix. *Digestive Surgery*, 2009, 26(2): 115-116.
- [2] M. Gentile, V. Guarino, F. Mosella, et al. Giant mucocele of the appendix. Case report and review of the literature. *Annali Italiani Chirurgia*, 2008, 79(4): 293-297.
- [3] M. Pitiakoudis, A. K. Tsaroucha, K. Mimidis, et al. Mucocele of the appendix: A report of five cases. *Techniques in Coloproctology*, 2004, 8(2): 109-112.