

# 腰椎神经鞘瘤1例诊治分析并文献复习

祁乐, 刘钦毅\*

吉林大学第二医院脊柱外科, 吉林 长春

收稿日期: 2022年5月21日; 录用日期: 2022年6月11日; 发布日期: 2022年6月23日

## 摘要

神经鞘瘤又称神经膜纤维瘤或者雪旺瘤, 是一种起源于神经鞘结构的肿瘤, 性质为良性, 多呈单发性生长, 好发部位主要位于脊神经后根和肋间神经, 其次为交感神经、迷走神经和喉返神经。根据组织结构特点可分为致密型和网状型两种, 该病最常见于40~60岁的中年人及有神经鞘瘤家族病史者, 临床典型症状为肿物压迫神经导致的肢体酸麻感、感觉及运动障碍。本病非手术治疗难以治愈, 手术治疗方法是主要的治疗手段。

## 关键词

腰椎, 神经鞘瘤, 诊治, 外科治疗

# Analysis of the Diagnosis and Treatment of Lumbar Schwannoma: A Case Report and Literature Review

Le Qi, Qinyi Liu\*

The Department of Spine Surgery, The Second Hospital of Jilin University, Changchun Jilin

Received: May 21<sup>st</sup>, 2022; accepted: Jun. 11<sup>th</sup>, 2022; published: Jun. 23<sup>rd</sup>, 2022

## Abstract

Schwannoma is a kind of tumor which often originates from the nerve sheath and it is always benign in nature. Besides, the disease is mostly solitary in growth and the preferred sites are mainly located in the posterior spinal nerve roots and intercostal nerves, followed by the sympathetic

\*通讯作者。

nerve, vagus nerve and the recurrent laryngeal nerve. They can be divided into two types, dense and reticulated according to the structural characteristics of the tissue. The disease is most common in middle-aged people aged 40~60 years old and in those with a family history of nerve sheath tumor. The typical clinical symptoms are numbness, sensory and motor impairment as a result of compressing nerve by the swelling. The disease is difficult to be cured by non-surgical treatment. So the surgical treatment is the main treatment method.

## Keywords

Lumbar, Schwannoma, Diagnose and Treatment, Surgical Treatment

Copyright © 2022 by author(s) and Hans Publishers Inc.

This work is licensed under the Creative Commons Attribution International License (CC BY 4.0).

<http://creativecommons.org/licenses/by/4.0/>



Open Access

## 1. 介绍

神经鞘瘤是位于椎管内最常见的肿瘤之一[1] [2] [3], 起源于神经根鞘, 绝大多数为良性肿瘤, 生长缓慢, 呈单发局限性生长, 很少侵蚀骨骼[4], 有时它们表现出脊柱的侵袭性和溶骨性破坏的特征, 使其难以与恶性脊柱肿瘤区分开来[5]。该病最常见于 40~60 岁的中年人及有神经鞘瘤家族病史者, 发病率大约在 0.3/10 万~0.4/10 万[6]。由于肿瘤生长缓慢, 传统的神经鞘瘤可以长时间保持无症状。最常见的症状是局部疼痛, 其次是神经系统症状[7]。当病情进展后, 典型症状是夜间痛, 躺下时加重, 无缓解期[8], 后期还会出现感觉减弱、肌力下降和自主神经功能障碍的症状。在报道的位于腰椎的神经鞘瘤中, L5 节段受累的发生率最高, 可能因为其神经根的长度较长, 尺寸较大[9]。肿瘤瘤体肉眼观多有完整的包膜, 切面可呈淡红、灰白或黄色多数为不规则分叶状和卵圆形, 少数呈球形, 有时可见由变性而形成的囊肿, 内含血性液体。

## 2. 案例介绍

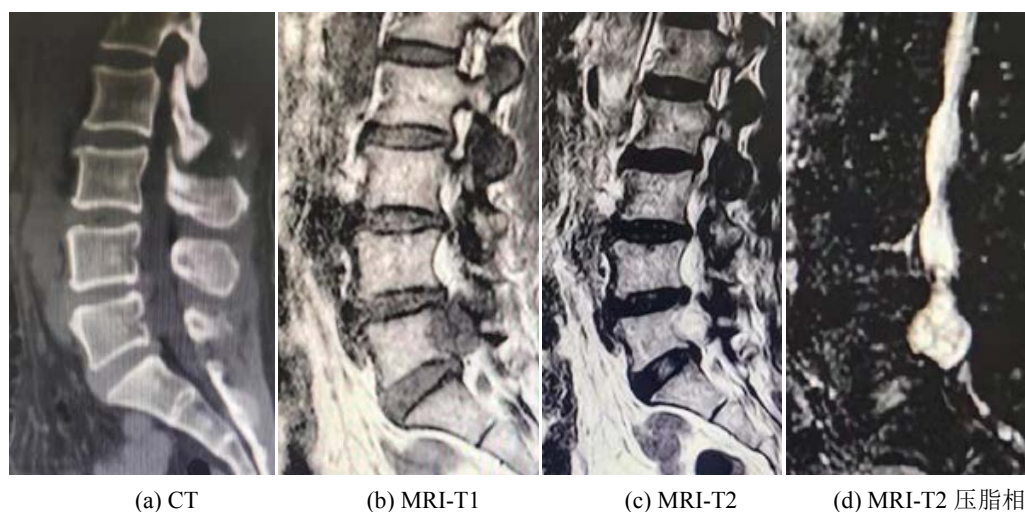
### 2.1. 病史采集

患者女, 54 岁, 主因“左下肢麻木疼痛 1 年, 加重 2 个月”入院。

现病史: 患者 1 年前无明显诱因出现左侧腰部、左侧臀部及左下肢后侧麻木疼痛, 行保守治疗无效, 2 个月前上述症状加重, 现患者为求进一步诊治来我院门诊就诊, 门诊给予磁共振腰椎平扫加增强影像后示: L5 椎体水平椎管内占位性病变。我院遂以“脊髓肿瘤(性质待定)”收入院, 既往史、个人史均无特殊情况。

专科查体: 视诊: 脊柱生理曲度存在, 触诊: 腰部压痛阳性, 叩击痛阴性。皮肤感觉: 左下肢外侧及后侧感觉减退。四肢运动: 髂腰肌肌力: 左侧 III 级, 右侧 IV 级; 股四头肌: 左侧 III 级, 右侧 IV 级; 胫骨前肌: 左侧 III 级, 右侧 IV 级; 踇长伸肌: 左侧 III 级, 右侧 IV 级; 肌张力未见明显异常。生理反射: 左侧膝腱反射减弱, 右侧正常; 双下肢跟腱反射正常。病理反射: 双侧 Hoffman(-), 双侧 Babinski(-), 双侧髌阵挛及踝阵挛引出。左下肢直腿抬高试验及加强试验阳性, 双下肢末梢血循未见明显异常。

辅助检查: 腰椎 CT 示: L5 水平椎管内低密度影, 详见图 1(a); 腰椎核磁共振示: L5 水平椎管内占位性病变, 详见图 1(b)~(d)。

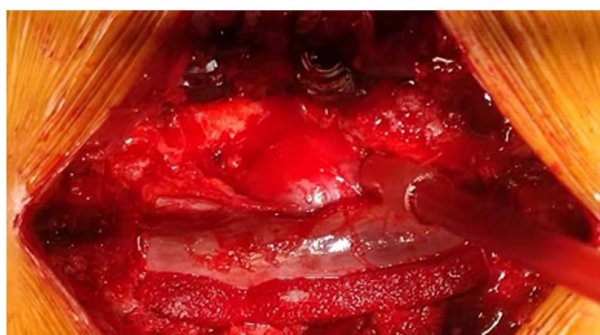


**Figure 1.** Patient's preoperative imaging results  
**图 1.** 患者术前影像学检查结果

## 2.2. 诊治经过

鉴于患者病情, 给予腰椎后路椎板切除 + 脊髓肿瘤切除术, 患者取俯卧位, 全麻生效后, 开始手术。当咬骨钳咬除相应节段棘突, 椎板钳咬除椎板后, 神经剥离子分离并咬除黄韧带及周围粘连组织, 充分显露硬膜囊及神经根, 在左侧神经根包膜内可见一巨大肿物, 详见图 2, 切开神经根外膜, 见肿物与神经完全粘连在一起, 仔细清理神经与肿物界限, 切除肿物, 充分减压神经根, 完成手术。术后对肿物进行病检, 结果显示为神经鞘瘤。

术后患者生命体征平稳, 左下肢症状较术前明显减轻。根据患者引流管内液体的颜色和量, 我们于术后第 4 天拔除引流管, 在术后 1 个月时, 指导其在严格佩戴腰部支具后方可下地活动。术后随访 12 个月后, 现患者恢复良好, 未出现任何神经压迫症状及其他不适症状。



**Figure 2.** Patient's intraoperative mass  
**图 2.** 患者术中肿物

## 3. 讨论

### 3.1. 诊断及鉴别诊断

神经鞘瘤通常为软组织肿瘤, 在 X 线上难以显影。MRI 被认为是最为准确、有效的诊断方法, 可以清晰显示肿瘤大小、神经受压的部位和程度[10]。此外对应节段的椎体也会出现一系列变化, 包括椎弓根

破坏、椎管扩张、椎体改变(后部扇形)、椎弓根间距增加等[11], 神经鞘瘤还会导致相邻骨结构的压力侵蚀, 可能是由沿脊神经支扩散的神经鞘瘤引起的。本例患者占位病变位于 L5 水平椎管内, T1 相呈低信号, T2 相和压脂相呈高信号, L5 椎体后方呈明显扇形侵蚀该病, 瘤体与脊髓界限不清, 难以诊断为髓内还是髓外肿瘤。术前还需与室管膜瘤或血管海绵体瘤进行鉴别诊断, 且这些肿瘤均为良性肿瘤。由于肿瘤位于椎管中, 不足以进行安全穿刺活检[12]。因此, 我们决定直接进行肿瘤切除。

### 3.2. 治疗及术后并发症

目前临床医师认为手术切除椎管内神经鞘瘤是最佳的治疗方式, 因为手术不仅可以解除肿瘤对脊髓或者神经根的压迫, 恢复脊髓和神经功能, 而且早期行手术治疗可取得较好的疗效[13]。有学者认为对于神经鞘瘤的切除既可以采用病灶内的局部切除, 也可以采用肿物全部切除这两种方法。Fehlings 等人[14]曾对 169 例病例进行两种方法的回顾性分析, 发现病灶内切除病例的复发率是整块切除病例的四倍。Li [15]认为整块切除方法可以显著改善患者症状, 术后患者功能大幅恢复。手术入路包括前路和后路, 几乎所有情况下, 脊柱病变都需要后路减压[16]。当病变位于脊髓外侧时, 可以通过后路入路轻松切除, 无需小关节切除术[17]。因此我们采取经后路全椎板切除术进行切除肿瘤并减压神经根和脊髓, 术中见肿瘤与神经根粘连严重, 仔细分离后, 经过一年随访患者下肢运动和感觉功能完全恢复, 未残留功能障碍。在某些情况下, 神经鞘瘤切除后仅检测到轻微神经功能缺损, 其原因是受累神经可能在手术前已被邻近根部功能代偿[18]。但患者在手术后出现足背外侧轻度无力和 L5 皮节麻木。此外, 术后患者还会出现硬脊膜外血肿、脊髓水肿和脑脊液漏等, 因此, 有必要与患者进行术前讨论和解释术后神经功能障碍的可能性[19]。

## 4. 总结

综上所述, 对于椎管内的肿瘤, 我们要根据影像学检查结果及患者的神经症状和查体等结果制定相应的个体化治疗方案。现如今手术治疗已达成共识, 绝大多数病例均可通过标准的后路椎板切开, 肿瘤全切除, 及早解除肿瘤对脊髓和神经的压迫, 显著恢复神经功能, 进而达到治愈。

## 同意书

本病例报告资料搜集及发表已获得病人及授权人的知情同意。

## 参考文献

- [1] Ledbetter, L.N. and Leever, J.D. (2019) Imaging of Intraspinous Tumors. *Radiologic Clinics of North America*, **57**, 341-357. <https://doi.org/10.1016/j.rcl.2018.09.007>
- [2] Wu, Y.L., Chang, C.Y., Hsu, S.S., Yip, C.-M., Liao, W.-C., Chen, J.-Y., et al. (2014) Intraspinous Tumors: Analysis of 184 Patients Treated Surgically. *Journal of the Chinese Medical Association*, **77**, 626-629. <https://doi.org/10.1016/j.jcma.2014.08.002>
- [3] Duong, L.M., Mccarthy, B.J., Mclendon, R.E., Dolecek, T.A., Kruchko, C., Douglas, L.L., et al. (2012) Descriptive Epidemiology of Malignant and Nonmalignant Primary Spinal Cord, Spinal Meninges, and Cauda Equina Tumors, United States, 2004-2007. *Cancer*, **118**, 4220-4227. <https://doi.org/10.1002/cncr.27390>
- [4] Engelhard, H.H., Villano, J.L., Porter, K.R., Stewart, A.K., Barua, M., Barker, F.G., et al. (2010) Clinical Presentation, Histology, and Treatment in 430 Patients with Primary Tumors of the Spinal Cord, Spinal Meninges, or Cauda Equina. *Journal of Neurosurgery: Spine SPI*, **13**, 67-77. <https://doi.org/10.3171/2010.3.SPINE09430>
- [5] Yang, K.S., Ho, C.S., Tai, P.A. and Kung, W.M. (2018) Intraspinous Schwannoma and Neurogenic Bladder. *Annals of The Royal College of Surgeons of England*, **100**, e69-e72. <https://doi.org/10.1308/rcsann.2018.0002>
- [6] Celli, P., Trillò, G. and Ferrante, L. (2005) Spinal Extradural Schwannoma. *Journal of Neurosurgery: Spine*, **2**, 447-456. <https://doi.org/10.3171/spi.2005.2.4.0447>
- [7] Uchiyama, T., Sakakibara, R., Hattori, T. and Yamanishi, T. (2004) Lower Urinary Tract Dysfunctions in Patients with

- Spinal Cord Tumors. *Neurourology and Urodynamics*, **23**, 68-75. <https://doi.org/10.1002/nau.10070>
- [8] Jankowski, R., Szmaja, J., Nowak, S., Sokół, B. and Blok, T. (2010) Giant Schwannoma of the Lumbar Spine. A Case Report. *Neurologia i Neurochirurgia Polska*, **44**, 91-95. [https://doi.org/10.1016/S0028-3843\(14\)60410-2](https://doi.org/10.1016/S0028-3843(14)60410-2)
- [9] Chiang, E.R., Chang, M.C. and Chen, T.H. (2009) Giant Retroperitoneal Schwannoma from the Fifth Lumbar Nerve Root with Vertebral Body Osteolysis: A Case Report and Literature Review. *Archives of Orthopaedic and Trauma Surgery*, **129**, 495-499. <https://doi.org/10.1007/s00402-008-0635-5>
- [10] Jellema, K., Overbeeke, J.J., Teepe, H.L. and Visser, L.H. (2005) Time to Diagnosis of Intraspinous Tumors. *European Journal of Neurology*, **12**, 621-4. <https://doi.org/10.1111/j.1468-1331.2005.01043.x>
- [11] Inaoka, T., Takahashi, K., Hanaoka, H., Aburano, R., Tokusashi, Y., Matsuno, T., *et al.* (2001) Paravertebral Neurofibroma Associated with Aggressive Intravertebral Extension. *Skeletal Radiology*, **30**, 286-289. <https://doi.org/10.1007/s002560100327>
- [12] Zhong, B., Shao, Z. and Pan, H. (2020) Intraspinous Canal Schwannoma with Extensive Calcification: Case Report and Literature Review. *World Neurosurgery*, **134**, 555-559. <https://doi.org/10.1016/j.wneu.2019.11.099>
- [13] Liu, C., Yan, L., Liu, Q., Li, J., Jin, H., Wang, J., *et al.* (2018) Lumbar Intraspinous Microcystic/Reticular Schwannoma: Case Report and Literature Review. *Medicine*, **97**, e12474. <https://doi.org/10.1097/MD.00000000000012474>
- [14] Fehlings, M.G., Nater, A., Zamorano, J.J., Tetreault, L.A., Varga, P.P., Gokaslan, Z.L., *et al.* (2016) Risk Factors for Recurrence of Surgically Treated Conventional Spinal Schwannomas: Analysis of 169 Patients from a Multicenter International Database. *Spine*, **41**, 390-398. <https://doi.org/10.1097/brs.0000000000001232>
- [15] Li, B., Yin, H., Meng, T., Zhou, P., Han, Z., Jia, Q., *et al.* (2016) Clinical Features and Prognostic Factors of Patients with Nerve Sheath Tumors in the Cervical Spine. *Spine*, **41**, E1208-E1215. <https://doi.org/10.1097/BRS.0000000000001595>
- [16] Bhat, A.R., Kirmani, A.R., Wani, M.A. and Bhat, M.H. (2016) Incidence, Histopathology, and Surgical Outcome of Tumors of Spinal Cord, Nerve Roots, Meninges, and Vertebral Column—Data Based on Single Institutional (Sher-i-Kashmir Institute of Medical Sciences) Experience. *Journal of Neurosciences in Rural Practice*, **7**, 381-391. <https://doi.org/10.4103/0976-3147.181489>
- [17] Xia, L.L., Tang, J. and Huang, S.L. (2021) Primary Intraspinous Benign Tumors Treated Surgically: An Analysis from China. *British Journal of Neurosurgery*, **35**, 603-606. <https://doi.org/10.1080/02688697.2021.1923648>
- [18] Schultheiss, R. and Gullotta, G. (1993) Resection of Relevant Nerve Roots in Surgery of Spinal Neurofibromas without Persisting Neurological Deficit. *Acta Neurochirurgica*, **122**, 91-96. <https://doi.org/10.1007/BF01446992>
- [19] Li, B., Li, J., Miao, W., Zhao, Y., Jiao, J., Wu, Z., *et al.* (2018) Prognostic Analysis of Clinical and Immunohistochemical Factors for Patients with Spinal Schwannoma. *World Neurosurgery*, **120**, e617-e627. <https://doi.org/10.1016/j.wneu.2018.08.135>