

# 以右上臂肿物为首发表现的肺低分化腺癌1例 与文献回顾

卞亚南<sup>1</sup>, 李 钊<sup>2\*</sup>, 王法腾<sup>1</sup>

<sup>1</sup>济宁医学院临床医学院, 山东 济宁

<sup>2</sup>济宁医学院附属医院呼吸与危重症医学科, 山东 济宁

收稿日期: 2024年1月7日; 录用日期: 2024年2月1日; 发布日期: 2024年2月8日

## 摘 要

目的: 通过1例罕见以右上臂皮下转移为首发症状的肺癌病例, 指导临床医生及时确定原发部位, 尽早做出正确诊断和个体化治疗, 延长患者生存期。方法: 回顾性分析该例肺低分化腺癌皮肤转移的临床特点、病理学特征、诊断及鉴别诊断、治疗及预后, 并复习相关文献。结果: 超声检查皮下见极低回声团块, 胸部增强CT示左肺上叶尖后段不规则形分叶状肿块; 右上臂肿物及左肺上叶活检病理均显示低分化腺癌, 表现为一致的肿瘤细胞特征, 结合免疫组化, 证实右臂肿物癌是原发性肺腺癌的转移。行MDT后制定“培美曲塞二钠 + 卡铂全身化疗, 贝伐珠单抗抗肿瘤血管”方案, 经6个周期治疗后, 患者右上臂及左肺上叶肿块较前缩小, 皮下肿块疼痛减轻。结论: 皮肤转移可能是肺癌的首发征象, 尤其有长期大量吸烟史的患者, 当皮肤病变迅速出现时, 应考虑到肺癌伴皮肤转移可能。组织活检及免疫组化有助于精准诊断原发癌部位及组织学类型, 含铂双药化疗联合抗血管治疗是有效的治疗选择。

## 关键词

肺腺癌, 皮肤转移, 软组织转移, 吸烟, 治疗

# A Case of Poorly Differentiated Lung Adenocarcinoma with Right Upper Arm Mass as the First Presentation and Literature Review

Yanan Bian<sup>1</sup>, Zhao Li<sup>2\*</sup>, Fateng Wang<sup>1</sup>

<sup>1</sup>School of Clinical Medicine, Jining Medical College, Jining Shandong

<sup>2</sup>School of Respiratory and Critical Care Medicine, Affiliated Hospital of Jining Medical College, Jining Shandong

\*通讯作者。

## Abstract

**Objective:** To investigate a rare case of lung cancer with subcutaneous metastasis of the right upper arm as the first symptom, guide clinicians to identify the primary site in time, make correct diagnosis and individualized treatment as soon as possible, and prolong the survival of the patient. **Methods:** The clinical features, pathological features, diagnosis, differential diagnosis, treatment and prognosis of skin metastases in this case of lung poorly differentiated adenocarcinoma were retrospectively analyzed. **Results:** Very low echo mass was found subcutaneous by ultrasonography. Contrast-enhanced CT showed irregular lobular mass in posterior segment of left upper lobe. The biopsy pathology of the right upper arm mass and the left upper lobe of the lung showed poorly differentiated adenocarcinoma, showing consistent tumor cell characteristics. Combined with immunohistochemistry, the tumor of the right arm was confirmed as metastasis of primary lung adenocarcinoma. After MDT, the regimen of “Pemetrexed disodium + carboplatin systemic chemotherapy, bevacizumab anti-tumor blood vessels” was formulated. After 6 cycles of treatment, the masses of the patient’s right upper arm and left upper lobe of lung were smaller than before, and the pain of subcutaneous masses was relieved. **Conclusion:** Skin metastasis may be the first sign of lung cancer, especially in patients with a long history of heavy smoking. When skin lesions appear rapidly, the possibility of lung cancer with skin metastasis should be considered. Tissue biopsy and immunohistochemistry can help to accurately diagnose the site and histological type of the primary cancer, and platinum chemotherapy combined with antivascular therapy is an effective treatment option.

## Keywords

Lung Adenocarcinoma, Cutaneous Metastasis, Soft Tissue Metastasis, Smoking, Therapy

Copyright © 2024 by author(s) and Hans Publishers Inc.

This work is licensed under the Creative Commons Attribution International License (CC BY 4.0).

<http://creativecommons.org/licenses/by/4.0/>



Open Access

## 1. 引言

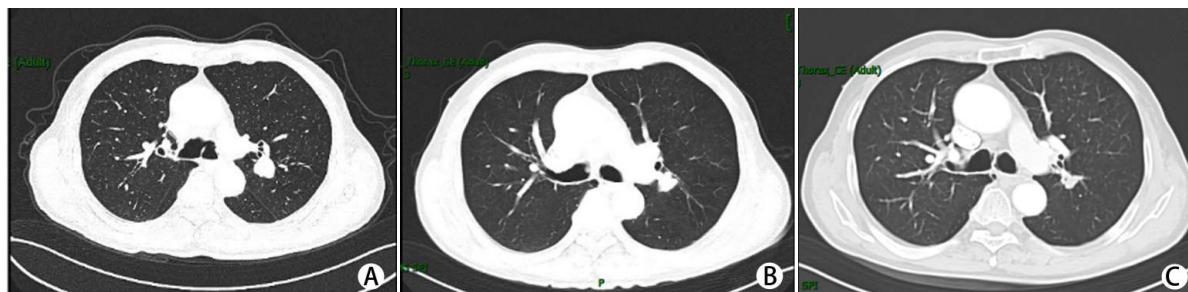2016 年国家癌症中心(National Cancer Center, NCC)发布的统计数据显示,肺癌是中国最常见的恶性肿瘤,无论是男性还是女性,肺癌的死亡率均居首位[1]。据流行病学调查报道,约 50%的肺癌患者在初诊时已经发生了远处转移。肺癌常见的转移部位为脑、骨、肝及肾上腺,转移到软组织,包括骨骼肌和皮肤组织,罕有报道,总体患病率为 2.3% [2] [3] [4]。以皮肤转移作为临床上无症状的内脏癌的第一征象更是极其罕见的,据报道,只有 0.8%的病例发生[5]。肺癌皮肤组织转移临床罕见,但却是重要的诊断线索。临床上由于原发性肺癌起病隐匿,常缺乏典型的呼吸道症状,而常被延误诊断,因此皮肤转移灶可能是临床隐匿性肺癌的第一个临床证据,通过组织活检及免疫组化等检查,有助于尽早发现原发部位肿瘤[6]。

## 2. 临床资料

患者,男性,76 岁,因“发现右上臂外侧有一鸡蛋大小肿物半月余”于 2023-01-25 日来诊。自觉右上臂肿物持续性隐痛,伴有右肩背部疼痛,否认有任何呼吸道症状、发烧或体重减轻。曾于汶上县人民

医院筛查胸部 CT 提示“肺部结节影”，未做特殊治疗。既往有长期大量吸烟史，40 支/天 × 50 余年。无特殊病史及家族史。体格检查：神志清，精神可。肿物质地坚硬，边界清，与周围组织无粘连，无出血或渗出，无压痛。其他体格检查未见明显异常。浅表肿物彩超检查示：右上臂皮下见极低回声团块，大小约 3.1 cm × 2.6 cm × 2.0 cm，界清，形态不规则，内回声不均，可及稀疏血流信号，与肌层关系密切。考虑占位性病变，倾向恶性病灶，肉瘤？转移灶？建议病理。

入院后，完善相关检查，肺癌相关的肿瘤标记物血清学检测提示：细胞角蛋白 19 片段(CYFRA 21-1): 4.030 ng/ml (0~3.3 ng/ml)，鳞状上皮细胞癌相关抗原(SCCAg) 1.6 ng/ml (0~1.5 ng/ml)，余实验室检测结果(如血常规、电解质、肝功、肾功、凝血常规等)未见明显异常；胸部增强 CT：可见左肺上叶尖后段见一不规则形分叶状肿块，大小约 30 mm × 29 mm × 34 mm，边缘欠规整，强化后可见肿物不均轻度强化(图 1A)，考虑：左肺上叶尖后段占位性病变；倾向于恶性肿瘤性病变。排除禁忌后行超声引导右上臂肿物穿刺活检术，病理回示：纤维结缔组织中查见低分化腺癌；免疫组化：肿瘤细胞 CK、CAM 5.2、Syn(+), TTF-1(少量+), P63、NapsinA、CD56、NSE、CgA(-), Ki-67(+, 8%~10%)(图 2A)。并行支气管镜检查，镜下可见左肺上叶后段支气管开口处新生物沿管壁浸润性生长，活检病理示：送检组织中查见异型细胞巢，结合免疫组化符合低分化癌，倾向低分化腺癌；免疫组化：CK(+), p40(个别+), CK5/6(局灶+), TTF-1(局灶+), NapsinA(-), CK7(-), Ki-67(+, 60%)(图 2B)。行颅脑 MRI 增强扫描、全身骨显像(ECT)、上腹部增强 CT 浅表淋巴结彩超检查进行全身评估未见明显肺癌转移征象。基因检测 EGFR、ALK、KRAS、BRAF 和 MET 等未见基因突变。分子检测程序性死亡配体-1 (PD-L1)检测结果：TPS < 1%。患者最终诊断左肺腺癌(T2N0M1 IV 期)、右臂转移癌。

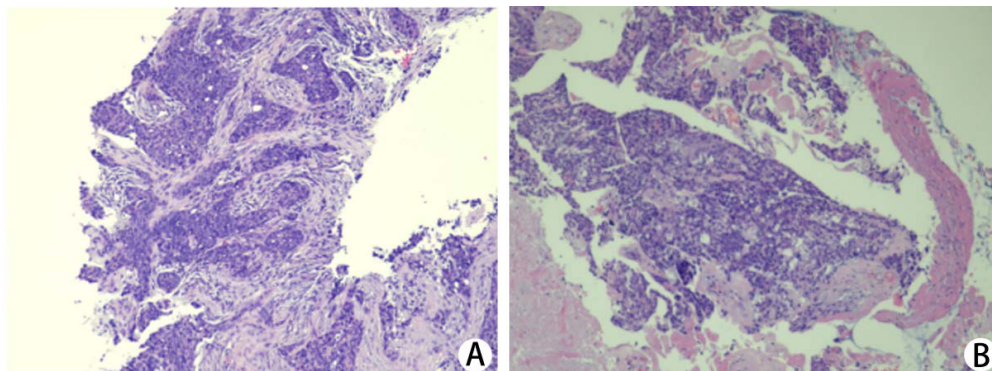


**Figure 1.** Chest direct enhanced CT images. A: Contrast-enhanced CT scan showed an irregular lobulated mass in the posterior segment of the upper lobe tip of the left lung; 2023-01-28 chest enhanced CT showed that the lesion size was about 30 mm × 29 mm × 34 mm; B: After 3 cycles of treatment, chest enhanced CT was reexamined on 2023-03-26, and the lesions were smaller than before, with a size of about 20 mm × 15 mm × 27 mm; C: After 5 cycles of treatment, chest enhanced CT was reexamined on 2023-06-17, and the lesions were smaller than before, and the current size was about 19 mm × 10 mm × 23 mm

**图 1.** 胸部直接增强 CT 图像。A：胸部增强 CT 左肺上叶尖后段见一不规则形分叶状肿块，边缘欠规整。2023-01-28 胸部增强 CT 示病变大小约 30 mm × 29 mm × 34 mm；B：治疗 3 周期后，2023-03-26 复查胸部增强 CT 病变较前缩小，大小约 20 mm × 15 mm × 27 mm；C：治疗 5 周期后，2023-06-17 复查胸部增强 CT 病变较前缩小，现大小约 19 mm × 10 mm × 23 mm

经全院 MDT 后，排除相关禁忌，制定“全身化疗 + 抗肿瘤血管生成”治疗方案，具体为：“培美曲塞二钠 500 mg d1 + 卡铂 500 mg d1 + 贝伐珠单抗 0.6g d1, q3w, ivgtt”，辅助盐酸昂丹司琼止呕，地塞米松预防过敏等。患者分别于 2023-02-06、2023-03-01、2023-03-26、2023-05-05、2023-06-17、2023-07-16 完成 6 周期的治疗，期间无恶心、呕吐，头疼、头晕，腹痛、腹泻，全身皮疹等不良反应。2023-03-26 复查胸部增强 CT：见左肺上叶尖后段见一不规则形分叶状肿块，较前缩小，现大小约 20 mm × 15 mm × 27 mm，边缘欠规整，强化后可见肿物不均轻度强化(图 1B)。2023-06-17 复查胸部增强 CT：与 2023-03-26 对比，胸部增强示：左肺上叶尖后段见一不规则形分叶状肿块，较前片缩小，现大小约 19 mm × 10 mm × 23

mm, 边缘欠规整, 强化后可见肿物不均轻度强化(图 1C)。患者 2023-07-16 末次住院, 随访至 6 周期治疗结束, 患者一般状态可, 皮肤病变对化疗药物反应良好, 右臂转移性肿块引起的疼痛减轻, 肿物较前缩小, 复查胸部增强 CT, 左肺上叶肿瘤较前缩小。2023-07-18 治疗结束办理出院。



**Figure 2.** A: Biopsy of the right upper arm mass; B: Pathological image of left upper lobe lung biopsy. Biopsies at both sites showed poorly differentiated tumors with round or oval cells, marked atypia, mitotic images, and nests of cells arranged in invasive growth (hematoxylin-eosin  $\times 100$ )

**图 2.** A: 右上臂肿物活检病理图片; B: 左肺上叶活检病理图片。两处部位活检组织均显示低分化肿瘤, 细胞呈圆形或卵圆形, 有明显的异形性, 可见核分裂像, 细胞排列呈巢团状的浸润性生长(苏木精 - 伊红  $\times 100$ )

### 3. 文献回顾

本文通过报道 1 例肺低分化腺癌右上臂皮肤转移患者的诊疗经过, 以“低分化肺腺癌和皮肤转移”为关键词, 系统查阅万方数据库、中国知网数据库和维普网数据库, 剔除重复报道, 无活检及缺乏病理诊断患者, 筛选出中文文献 74 篇; 以检索条件: (lung cancer OR lung carcinoma) AND (Subcutaneous OR Cutaneous) AND (metastatic OR metastasis)为检索词对 1990 年 1 月至 2023 年 4 月在 PubMed 发表的英文文献进行检索, 通过去重、删除资料不全文献, 共纳入临床相关文献 73 篇, 进行文献复习。综合文献分析, 肺癌皮肤转移仍属于罕见病。通过分析其临床表现、诊断及治疗方式, 以提高临床医生对肺癌罕见转移部位的认识、诊治能力。

皮肤转移癌的定义是恶性细胞从原发肿瘤部位扩散到皮肤真皮或皮下组织中, 与原发肿瘤不相邻的病变, 是癌症全身扩散的一种表现形式。乳腺、肺和胃肠道下部是相对常见的皮肤转移的原发部位, 最常转移到皮肤的肿瘤是女性的乳腺癌和男性的肺癌, 其他更容易转移到皮肤的肿瘤包括胃肠道癌; 实际上这些部位癌症转移到皮肤的概率很低, 在各种系列报道中, 内脏恶性肿瘤的总发病率估计为 0.7%~9% [7] [8] [9], 包括在一项包含 20,380 例患者的大型研究中, Krathen 等人研究表明内脏恶性肿瘤皮肤转移发生率约为 5.3% [10]。

肺癌皮肤转移是一种罕见的临床现象, 总体概率约为 0.8%~2.8% [5] [11] [12] [13]。目前普遍认为, 肺癌皮肤转移与肺癌分化程度和病理类型密切相关。病理分化程度越低, 肺外转移发生率越高, 关于肺癌皮肤转移的机制尚未完全阐明, 目前有多种假说, 最被广泛接受的假说是血行途径, 来自肺部恶性肿瘤的皮肤转移通常分化较差, 它们可侵入淋巴、血管系统, 但一般局限于皮肤的真皮深层网状组织和皮下脂肪中。转移的部位多出现在原发癌附近皮肤, 以胸背部最常见, 其次为腹壁及头面部。各种组织学类型的肺癌均可发生皮肤转移, 腺癌发生皮肤转移的频率高于其他组织学亚型, 组织病理学检查显示肺癌皮肤转移常为中分化至低分化腺癌 [14] [15]。但也有报道认为, 小细胞癌是最常转移到皮肤的肺癌的组织学类型 [16]。目前的研究, 肺癌的组织学类型与皮肤转移的发生之间的关系, 尚未确定皮肤转移发生率



最高的肺癌组织学类型。

根据最新中国肺癌诊疗指南，肺癌治疗应遵循多学科团队(MDT)和个性化治疗相结合的原则，治疗方案包括观察、手术、化疗、放疗、靶向治疗和免疫治疗，根据患者的表现状态(PS)、组织学类型、肿瘤受累和预后决定，通常是单独或联合应用[17]。皮肤受累作为原发肿瘤的局部转移或远处转移，通常预示着疾病晚期和预后不良，研究表明，皮肤转移癌一经确诊平均生存期为5个月[16][18]，最初出现皮肤转移的患者比在疾病过程中后期出现皮肤转移的患者的生存期短约3个月[12]。原发癌部位越早确诊，越早开始治疗，越有利于延长患者生存期。在大多数病例中，皮肤转移病灶治疗以原发癌为主，通过全身治疗即可消退，临床上全身化疗多是首选[2][19][20]，但也有病例采用局部放射治疗，尤其在转移部位出现剧烈疼痛或出血时，证明放疗是有效的[11][21]。

据国内外最新研究证明，吸烟仍然是肺癌发生的主要危险因素，约占所有肺癌的90%。40包/年的吸烟史会使肺癌风险增加20倍[17][22]。有大量吸烟史或肺癌的患者出现皮肤肿物时，在鉴别诊断时应考虑转移性皮肤病变的可能，它们可能是临床无症状的内脏癌的首次出现的体征，与原发癌同时发生或在之前发生[10][21][23][24]，是原发性肺部恶性肿瘤初诊甚至复发的第一个临床征象[12]。

#### 4. 讨论

病例中，原发性肺腺癌的最初表现是一个疼痛的、快速增长的皮下肿物，通过组织病理及免疫组化最终证实该右上臂肿物为肺来源转移。患者皮肤病变与左肺上叶癌诊断几乎同时出现，诊断上存在挑战。皮肤软组织的转移很容易被误诊为原发性软组织肿瘤，如原发性皮肤鳞状细胞癌、基底细胞癌、淋巴瘤、化脓性肉芽肿、纤维组织细胞瘤、脂肪瘤、血管瘤、粘液瘤等。诊断方法没有特异性，主要是组织学活检结合免疫组化检查，计算机断层扫描等影像学检查同样必不可少。组织学上，皮肤转移癌通常表现出与原发恶性肿瘤相似的特征，分化程度多相同，提示皮肤转移病变的活检可能有助于确定肺癌组织学类型，如甲状腺转录因子(TTF-1)作为一种谱系标记物，目前已被用作肺腺癌的诊断标志物和良好的预后指标[16]。本病例中通过对患者皮下肿物和肺组织活检，结合病理形态学表现及免疫组化发现两者均表现TTF-1、ki-67等阳性，原发和转移性病变的组织学相似，高度提示肺来源肿瘤，患者最终诊断肺腺癌伴皮肤转移。然而，免疫标记物既不是100%特异性，也不是100%敏感性。在最近的一项研究中，约70%的肺腺癌皮肤转移TTF-1呈阴性[8]，这可能是由于皮肤转移中腺癌的低分化特性所致，因此对于分化程度差的原发癌与转移癌，有必要进行广泛的免疫组化检查，并结合其他临床诊断检查结果等进行综合性分析。

#### 5. 结论

肺癌的皮肤转移并不常见，特别是对于皮肤转移是原发癌首表现的患者，可能存在诊断上的挑战，通过本例肺低分化腺癌皮肤转移的罕见特殊表现，提示临床医生在接诊皮肤肿物患者时，尤其在有肺癌高危因素的患者，如吸烟史，应高度怀疑肺癌皮肤转移的可能，可行组织活检及免疫组化明确原发癌来源及组织学类型，及时做出正确诊断，尽早开始治疗，以延长患者生存期。

#### 作者贡献

卞亚南负责文章的构思与设计、研究资料的收集与整理、论文撰写；李钊负责文章的质量控制及修订，并对文章整体负责、监督管理。王法腾进行研究资料的收集和整理。

#### 利益冲突说明

本文无利益冲突。

## 基金项目

济宁市重点研发计划(2022YXNS053)。

## 参考文献

- [1] Zheng, R., Zhang, S., Zeng, H., *et al.* (2022) Cancer Incidence and Mortality in China, 2016. *Journal of the National Cancer Center*, **2**, 1-9. <https://doi.org/10.1016/j.jncc.2022.02.002>
- [2] Lookingbill, D.P., Spangler, N. and Helm, K.F. (1993) Cutaneous Metastases in Patients with Metastatic Carcinoma: A Retrospective Study of 4020 Patients. *Journal of the American Academy of Dermatology*, **29**, 228-236. [https://doi.org/10.1016/0190-9622\(93\)70173-Q](https://doi.org/10.1016/0190-9622(93)70173-Q)
- [3] Perisano, C., Spinelli, M.S., Graci, C., *et al.* (2012) Soft Tissue Metastases in Lung Cancer: A Review of the Literature. *European Review for Medical and Pharmacological Sciences*, **16**, 1908-1914.
- [4] Tamura, T., Kurishima, K., Nakazawa, K., *et al.* (2015) Specific Organ Metastases and Survival in Metastatic Non-Small-Cell Lung Cancer. *Molecular and Clinical Oncology*, **3**, 217-221. <https://doi.org/10.3892/mco.2014.410>
- [5] Lookingbill, D.P., Spangler, N. and Sexton, F.M. (1990) Skin Involvement as the Presenting Sign of Internal Carcinoma. A Retrospective Study of 7316 Cancer Patients. *Journal of the American Academy of Dermatology*, **22**, 19-26. [https://doi.org/10.1016/0190-9622\(90\)70002-Y](https://doi.org/10.1016/0190-9622(90)70002-Y)
- [6] Sariaydin, M., Gunay, E., Ulasli, S., *et al.* (2016) An Unusual Metastasis of Lung Adenocarcinoma: Biceps Brachii Muscle. *Lung India*, **33**, 669-671. <https://doi.org/10.4103/0970-2113.192857>
- [7] Hussein, M.R. (2010) Skin Metastasis: A Pathologist's Perspective. *Journal of Cutaneous Pathology*, **37**, e1-e20. <https://doi.org/10.1111/j.1600-0560.2009.01469.x>
- [8] Guanziroli, E., Coggi, A., Venegoni, L., *et al.* (2017) Cutaneous Metastases of Internal Malignancies: An Experience from a Single Institution. *European Journal of Dermatology*, **27**, 609-614. <https://doi.org/10.1684/ejd.2017.3142>
- [9] Pajaziti, L., Hapciu, S.R., Dobruna, S., *et al.* (2015) Skin Metastases from Lung Cancer: A Case Report. *BMC Research Notes*, **8**, Article Number: 139. <https://doi.org/10.1186/s13104-015-1105-0>
- [10] Salemis, N.S., Veloudis, G., Spiliopoulos, K., *et al.* (2014) Scalp Metastasis as the First Sign of Small-Cell Lung Cancer: Management and Literature Review. *International Surgery*, **99**, 325-329. <https://doi.org/10.9738/INTSURG-D-13-00070.1>
- [11] Gupta, V., Bhutani, N., Marwah, N., *et al.* (2017) Scalp Metastasis as an Initial Presentation of Lung Adenocarcinoma: A Case Report and Literature Review. *International Journal of Surgery Case Reports*, **41**, 327-331. <https://doi.org/10.1016/j.ijscr.2017.10.060>
- [12] Bhattarai, B., Schmidt, M.F., Ghosh, M., *et al.* (2015) Lung Cancer with Skin and Breast Metastasis: A Case Report and Literature Review. *Case Reports in Pulmonology*, **2015**, Article ID: 136970. <https://doi.org/10.1155/2015/136970>
- [13] Nguyen, N.C., Chaar, B.T. and Osman, M.M. (2007) Prevalence and Patterns of Soft Tissue Metastasis: Detection with True Whole-Body F-18 FDG PET/CT. *BMC Med Imaging*, **7**, Article Number: 8. <https://doi.org/10.1186/1471-2342-7-8>
- [14] Hu, S.C., Chen, G.S., Wu, C.S., *et al.* (2009) Rates of Cutaneous Metastases from Different Internal Malignancies: Experience from a Taiwanese Medical Center. *Journal of the American Academy of Dermatology*, **60**, 379-387. <https://doi.org/10.1016/j.jaad.2008.10.007>
- [15] Dhambri, S., Zendah, I., Ayadi-Kaddour, A., *et al.* (2011) Cutaneous Metastasis of Lung Carcinoma: A Retrospective Study of 12 Cases. *Journal of the European Academy of Dermatology and Venereology*, **25**, 722-726. <https://doi.org/10.1111/j.1468-3083.2010.03818.x>
- [16] Marcoval, J., Penin, R.M., Llatjos, R., *et al.* (2012) Cutaneous Metastasis from Lung Cancer: Retrospective Analysis of 30 Patients. *Australasian Journal of Dermatology*, **53**, 288-290. <https://doi.org/10.1111/j.1440-0960.2011.00828.x>
- [17] 中国医师协会肿瘤医师分会, 中国医疗保健国际交流促进会肿瘤内科分会, 石远凯. IV 期原发性肺癌中国治疗指南(2023年版)[J]. *中华肿瘤杂志*, 2023, 45(1): 30.
- [18] Altintoprak, F., Baytekin, H.F. and Tasdemir, C. (2011) Primary Small Cell Carcinoma of the Lung Presenting with Breast and Skin Metastases. *The Korean Journal of Internal Medicine*, **26**, 207-209. <https://doi.org/10.3904/kjim.2011.26.2.207>
- [19] Lindqvist, J., Jekunen, A., Sihvo, E., *et al.* (2022) Effect of Adherence to Treatment Guidelines on Overall Survival in Elderly Non-Small-Cell Lung Cancer Patients. *Lung Cancer*, **171**, 9-17. <https://doi.org/10.1016/j.lungcan.2022.07.006>
- [20] Hussain, S.A., Manogna, D. and Shapiro, J. (2020) Metastatic Lung Adenocarcinoma with Occult Involvement of Glu-

- 
- teal Muscles as the Sole Site of Distant Metastases. *Cureus*, **12**, e9826. <https://doi.org/10.7759/cureus.9826>
- [21] Wang, X., Wang, H., Jia, B., *et al.* (2020) Cutaneous Metastasis as the First Presentation of Non-Small-Cell Lung Cancer with a BRAF Mutation: A Case Report. *OncoTargets and Therapy*, **13**, 13143-13149. <https://doi.org/10.2147/OTT.S282593>
- [22] Lariscy, J.T., Hummer, R.A. and Rogers, R.G. (2020) Lung Cancer Mortality among Never-Smokers in the United States: Estimating Smoking-Attributable Mortality with Nationally Representative Data. *Annals of Epidemiology*, **45**, 5-11. <https://doi.org/10.1016/j.annepidem.2020.03.008>
- [23] Liao, H., Wu, S., Karbowitz, S.R., *et al.* (2014) Cutaneous Metastasis as an Initial Presentation of Lung Adenocarcinoma with KRAS Mutation: A Case Report and Literature Review. *Stem Cell Investigation*, **1**, 6.
- [24] Haji, K., Sato, S., Yoneda, H., *et al.* (2021) Multidisciplinary Treatment of Skeletal Muscle Metastasis from Lung Cancer: A Case of Triceps Muscle Metastasis of Lung Squamous Cell Cancer. *Respiratory Medicine Case Reports*, **33**, Article ID: 101470. <https://doi.org/10.1016/j.rmcr.2021.101470>