

# 子宫弥漫大B细胞淋巴瘤1例

艾林峰<sup>1\*</sup>, 张晓菡<sup>2</sup>, 王晓艳<sup>3</sup>, 张晓磷<sup>1#</sup>

<sup>1</sup>三峡大学第一临床医学院介入放射科, 湖北 宜昌

<sup>2</sup>长江大学附属第一医院放射科, 湖北 荆州

<sup>3</sup>长江大学附属第一医院病理科, 湖北 荆州

收稿日期: 2023年10月6日; 录用日期: 2023年11月1日; 发布日期: 2023年11月7日

## 摘要

目的: 通过病例回顾, 提高对子宫弥漫大B细胞淋巴瘤的认识、诊断和治疗。方法: 总结1例经病理证实的子宫淋巴瘤患者的临床资料, 并复习相关文献资料。结果: 患者临床表现为右侧腰部肿块, 伴右侧腰疼。CT示子宫腔内见类圆形团块状影, 最大截面约为47 mm × 43 mm, 增强呈轻度强化; 子宫顶部见类圆形混杂密度影, 其内见多发点状钙化影。MR示宫颈部见团块状稍长T1稍长T2信号, 直径约44 mm, 病灶向上生长, DWI呈高信号, 增强呈明显不均匀强化, 延迟期呈低信号, 右侧髂血管旁及腹膜后见多发肿大淋巴结。子宫顶部见类圆形长T1短T2信号。术后病理确诊为宫腔弥漫大B细胞淋巴瘤。结论: 子宫弥漫大B细胞淋巴瘤发生率极低, 影像表现具有一定特征性, 综合其临床、影像表现可提高诊断率, 但确诊仍依赖于病理。

## 关键词

子宫, 弥漫大B细胞淋巴瘤, CT, MR

# Diffuse Large B-Cell Lymphoma of the Uterus: A Case Report

Linfeng Ai<sup>1\*</sup>, Xiaohan Zhang<sup>2</sup>, Xiaoyan Wang<sup>3</sup>, Xiaolin Zhang<sup>1#</sup>

<sup>1</sup>Department of Interventional & Radiology, The First College of Clinical Medicine, China Three Gorges University, Yichang Hubei

<sup>2</sup>Department of Radiology, The First Affiliated Hospital of Yangtze University, Jingzhou Hubei

<sup>3</sup>Department of Pathology, The First Affiliated Hospital of Yangtze University, Jingzhou Hubei

Received: Oct. 6<sup>th</sup>, 2023; accepted: Nov. 1<sup>st</sup>, 2023; published: Nov. 7<sup>th</sup>, 2023

\*第一作者。

#通讯作者。

文章引用: 艾林峰, 张晓菡, 王晓艳, 张晓磷. 子宫弥漫大 B 细胞淋巴瘤 1 例[J]. 临床医学进展, 2023, 13(11): 17281-17286. DOI: 10.12677/acm.2023.13112421

## Abstract

**Objective:** To improve the understanding, diagnosis and treatment of diffuse large B-cell lymphoma of the uterus through the cases review. **Methods:** The clinical data of a case of pathologically-proved diffuse large B-cell lymphoma of the uterus was reported and relevant literatures were reviewed. **Results:** The patient felt a lump in the right waist with back pain. CT showed a circular mass shadow in the uterine cavity, and the maximum cross-section was about 47 mm × 43 mm, and the tumor was slightly enhancing. On the top of the uterus, there was a roundish and mixed-density shadow with punctate calcifications. MR showed a slightly longer T1 and slightly longer T2 signal mass shadow in the cervix with a diameter of 44 mm. The lesion grew upward. It showed high signal on DWI, significantly inhomogeneous enhancement, and delayed stage showed low signal. Multiple enlarged lymph nodes were seen around the right iliac vessel and retroperitoneum. A long T1 and short T2 signal round shadow were seen at the top of the uterus. The pathological diagnosis of the gallbladder lesion was diffuse large B-cell lymphoma of the uterus. **Conclusion:** The incidence of large B-cell lymphoma of the uterus is extremely low, and the imaging manifestations have certain characteristics. The overall clinical data and imaging manifestations can improve the diagnosis rate, but its diagnosis still depends on the pathology.

## Keywords

Uterus, Diffuse Large B-Cell Lymphoma, CT, MR

Copyright © 2023 by author(s) and Hans Publishers Inc.

This work is licensed under the Creative Commons Attribution International License (CC BY 4.0).

<http://creativecommons.org/licenses/by/4.0/>



Open Access

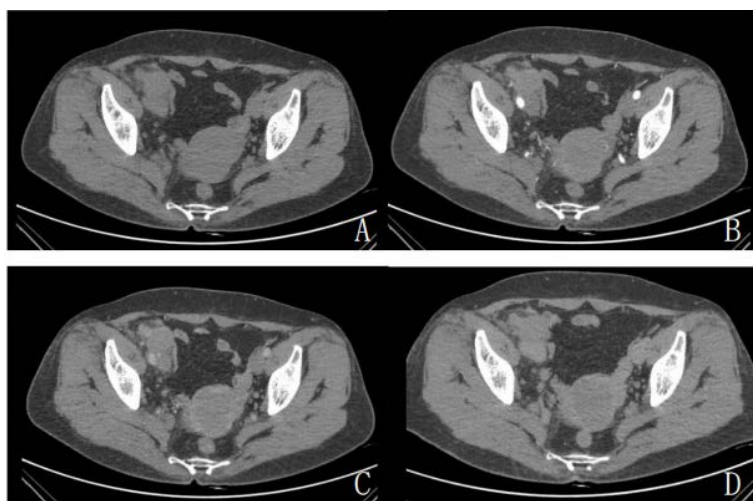
## 1. 引言

淋巴瘤是一种起源于淋巴结或结外淋巴组织中淋巴细胞的恶性肿瘤，按其病理特征可分为霍奇金淋巴瘤和非霍奇金淋巴瘤(约占所有淋巴瘤的 90%) [1]。非霍奇金淋巴瘤约 30%起自于结外部位，最常见的部位是胃肠道、皮肤、骨骼和中枢神经系统[2]，而女性生殖道结外淋巴瘤仅占 0.2%~1.1% [3]。而在女性原发生殖道淋巴瘤中，子宫淋巴瘤仅占 16.5%，以弥漫性大 B 细胞淋巴瘤(diffuse large B-cell lymphoma of the uterus, DLBCL)为主要病理类型[4] [5]。子宫 DLBCL 发病率低，临床症状不明确，临床上诊断困难，容易误诊，目前尚无标准的治疗方案。笔者回顾性分析 1 例经病理证实的子宫弥漫大 B 细胞淋巴瘤患者的临床、影像、病理资料，并查阅相关文献，以提高对本病的认识和影像诊断水平。

**病例简介:** 患者女，63 岁，1 周前无明显诱因下发现右侧腰部肿块，伴右侧腰疼，未行特殊治疗。患者有糖尿病病史 3 年。子宫颈肥大，后唇可见一蚕豆大小凸起，表面光整，无摇举痛，无接触性出血。子宫平位，增大如孕 2 月余大小，活动度差，无压痛。右侧附件区广泛增厚/固定，无压痛，左侧附件区未触及明显异常。实验室检查：糖类抗原 CA19-9 83.30 IU/ml。患者自本次发病以来，精神可，胃纳可，大便如常，小便如常，体重未见明显下降。

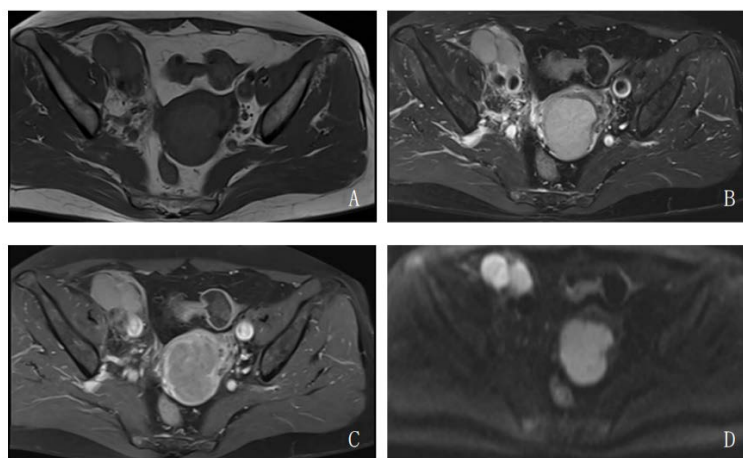
**辅助检查:** 1) CT: 子宫腔内见类圆形团块状影，最大截面约为 47 × 43 mm，增强呈轻度强化；子宫顶部见类圆形混杂密度影，其内见多发点状钙化影(图 1)。2) MRI: 宫颈部见团块状稍长 T1 稍长 T2 信号，直径约 44 mm，病灶向上生长，DWI 呈高信号，增强呈明显不均匀强化，延迟期呈低信号；子宫顶部见类圆形长 T1 短 T2 信号。腹膜后偏右侧及右侧髂血管旁可见多发结节状及团块状等 T1 稍长 T2 信号灶，

部分病灶内见囊状长 T2 信号，病灶最大截面约 120 mm × 75 mm，右侧输尿管及下腔静脉受侵，右侧肾盂、肾盏积水扩张，病灶与右侧腰大肌部分分界模糊，病灶邻近腰 4 椎体右侧见斑片状稍长 T2 信号灶，于 DWI 上病灶示扩散受限，增强后可见右侧髂总动脉及分支穿行其中，病灶包绕血管，病灶不均匀轻度强化，部分可见无强化坏死区(图 2)。



**Figure 1.** CT showed a circular mass shadow in the uterine cavity, and the maximum cross-section was about 47 mm × 43 mm, and the tumor was slightly enhancing

**图 1.** CT 示子宫腔内见类圆形团块状影，最大截面约为 47 mm × 43 mm，增强呈轻度强化

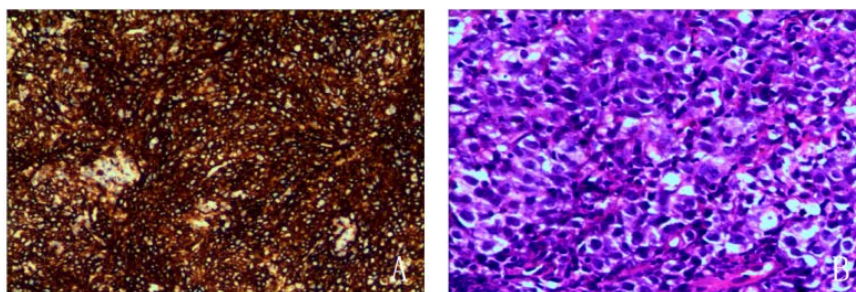


**Figure 2.** MR showed a slightly longer T1 and slightly longer T2 signal mass shadow in the cervix with a diameter of 44 mm. The lesion grew upward. It showed high signal on DWI and significantly inhomogeneous enhancement

**图 2.** MR 示宫颈部见团块状稍长 T1 稍长 T2 信号，直径约 44 mm，病灶向上生长，DWI 呈高信号，增强呈明显不均匀强化

介入超声引导下右侧腹膜后包块穿刺活检术 + 造影 + 经皮右肾造瘘术：患者左侧卧位，取腋前线肋缘下为穿刺点，常规消毒、铺巾，以 1%利多卡因局麻，在超声引导下以导丝法将 10Fr.引流管置入右侧扩张肾盂内，将引流管固定于腹壁。患者平卧位，取右下腹为穿刺点，常规消毒、铺巾，以 1%利多卡因局麻，在超声引导下将活检针穿入右侧腹膜后包块内，取出长约 2 cm 组织条 3 条，送检。

术后病理报告：(右侧腹膜后)非霍奇金淋巴瘤，B 细胞性，考虑为弥漫大 B 细胞淋巴瘤，非 GCB 亚型，免疫组化：PCK (-) CD3 (-) CD20 (+) CD21 (-) CD30 (-) Bcl-2 (+) Bcl-6 (+) MUM-1 (+)，CD10 (-) C-myc (±) P53 (+, 野生型) CD23 (-) CD43 (-) CD5 (+) CyclinD1 (-) SOX-11 (-)，Ki67 Li 约 70%，原位分子杂交：EBER (-)(图 3)。



**Figure 3.** (A) Immunoreactive CD20 cells; (B) diffuse large B-cell lymphoma, HE,  $\times 200$   
**图 3.** (A) 免疫反应性 CD20 细胞; (B) 弥漫大 B 细胞淋巴瘤, HE,  $\times 200$

## 2. 讨论

子宫 DLBCL 是一种极其罕见且鲜有报道的疾病，宫颈淋巴瘤占宫颈恶性肿瘤的 0.008% [6]。通常发生在绝经后妇女中。它的病因像大多数结外淋巴瘤一样，尚不清楚。

子宫 DLBCL 的临床表现缺乏特异性[7]，患者通常表现为异常子宫出血、腹部或盆腔不适[8]，少数患者因膀胱或输尿管受压而出现尿路症状，如尿频、尿急或肾积水，我们的患者即发生了右肾积水，一些无症状的患者在妇科检查中发现子宫增大。只有 17% 的非霍奇金淋巴瘤患者会出现全身症状，如发热、盗汗或体重减轻，而子宫非霍奇金淋巴瘤很少出现这些症状[9]。

在影像方面，子宫 DLBCL 具有一定的特异性。CT 表现为子宫弥漫性增大，边界不清，偶可见低密度液化坏死或囊变区，增强扫描淋巴瘤多为轻度强化，液化坏死、出血或囊变区域可无强化，可伴腹膜后、腹沟股及大血管旁的淋巴结转移。MR 表现为子宫弥漫性增大，信号均匀，弥漫全层，未干扰正常轮廓，T1 加权呈均匀低信号，T2 加权呈略高信号[10]，T1WI 增强呈轻度强化，这可能由于瘤细胞在血管周围袖套样生长，造成血管内皮损伤，侵犯血管壁，进入管腔，从而造成病灶强化。DWI 为显著高信号。PET-CT 被认为是淋巴瘤分期测定的一种高度阳性和特异的方法。从影像学研究的角度来看，PET-CT 已成为诊断和患者病情进展监测的首选方法，有时与 MRI 交替使用[11] [12]。

在有上述影像表现的情况下，应使用活检组织病理学评估以进一步明确诊断。子宫 DLBCL 病理组织学表现为弥漫性大细胞浸润，形态较均一，免疫表型分析均表达 CD20、PAX5、CD79a，无 CD3、CD43、CD45RO 表达，主要表达 bcl6、CD10、MUM1、EMA [13]。

子宫淋巴瘤的临床症状与女性生殖器官恶性肿瘤类似[14]，尤其是子宫颈癌和子宫内膜癌，在影像上，后两者均可表现为子宫颈、宫体体积增大伴软组织肿块，中晚期病变也可侵犯邻近组织，但是，子宫淋巴瘤在影像上多表现为密度或信号均匀的软组织肿块，而子宫颈、子宫内膜癌如体积较大多合并坏死，如同时有坏死或囊变，单纯依靠影像学检查很难鉴别，须依靠病理学检查。此外，子宫淋巴瘤还需与宫颈淋巴上皮瘤样癌相鉴别，它是一种特殊类型的恶性肿瘤，是宫颈鳞状细胞癌的一种罕见变异类型，临床表现为无明显诱因或性生活后阴道不规则流血，伴或不伴腰腹疼痛、腰骶部坠胀感。MRI 平扫呈稍长 T1、稍长 T2 信号，大部分信号均匀，部分病灶密度欠均匀，中央可见坏死区，T1 增强呈明显渐进性强化，坏死区无强化。



子宫 DLBCL 是一种罕见疾病, 因此最佳治疗方法尚未达成共识[15][16]。治疗方案有以下三种: 1) 化疗: 常用化疗方案为 CHOP (环磷酰胺、阿霉素、长春新碱、强的松龙); 2) 手术治疗: 淋巴瘤被认为对化疗和放疗敏感[17], 因此手术治疗受到限制。手术的主要目的是获取病理信息, 明确诊断。手术主要用于宫颈活检和锥切术, 子宫切除术很少见[18][19][20]。不主张扩大手术范围, 化疗是治疗过程中的重点[21]; 3) 综合治疗: 指术前新辅助化疗或术前同步放化疗。

如果及早发现并治疗, 这种疾病的预后非常好, 5 年生存率为 80% [21]。因此, 在早期阶段诊断这种疾病至关重要。子宫 DLBCL 的预后与年龄、疾病分期[5]、治疗方式[22]和免疫表型有关, 淋巴结受累程度和体能状态也被文献引用为预后因素[18]。CD10 阳性和 Bcl-6 阳性的 5 年生存率较高, 分别为 88.9% 和 81.8%。然而, CD10 阴性和 Bcl-6 阴性的 5 年生存率较低, 分别为 25.0%和 33.3% [13]。

## 参考文献

- [1] Armitage, J.O., Gascoyne, R.D., Lunning, M.A., *et al.* (2017) Non-Hodgkin Lymphoma. *The Lancet*, **390**, 298-310. [https://doi.org/10.1016/S0140-6736\(16\)32407-2](https://doi.org/10.1016/S0140-6736(16)32407-2)
- [2] Vannata, B. and Zucca, E. (2015) Primary Extranodal B-Cell Lymphoma: Current Concepts and Treatment Strategies. *Chinese Clinical Oncology*, **4**, 10.
- [3] Lagoo, A.S. and Robboy, S.J. (2006) Lymphoma of the Female Genital Tract: Current Status. *International Journal of Gynecological Pathology*, **25**, 1-21. <https://doi.org/10.1097/01.pgp.0000183049.30212.f9>
- [4] Kosari, F., Daneshbod, Y., Parwaresch, R., *et al.* (2005) Lymphomas of the Female Genital Tract a Study of 186 Cases and Review of the Literature. *The American Journal of Surgical Pathology*, **29**, 1512-1520. <https://doi.org/10.1097/01.pas.0000178089.77018.a9>
- [5] Nasioudis, D., Kampaktsis, P.N., Frey, M., *et al.* (2017) Primary Lymphoma of the Female Genital Tract: An Analysis of 697 Cases. *Gynecologic Oncology*, **145**, 305-309. <https://doi.org/10.1016/j.ygyno.2017.02.043>
- [6] Mandato, V.D., Palermo, R., Falbo, A., *et al.* (2014) Primary Diffuse Large B-Cell Lymphoma of the Uterus: Case Report and Review. *Anticancer Research*, **34**, 4377-4390.
- [7] 刘颖, 曹子龙, 张蕾, 等. 子宫非霍奇金淋巴瘤 1 例[J]. 中国临床医学影像杂志, 2021, 32(1): 72-73.
- [8] Agrawal, A., Ofili, G., Allan, T., *et al.* (2000) Malignant Lymphoma of Uterus: A Case Report with a Review of the Literature. *Australian and New Zealand Journal of Obstetrics and Gynaecology*, **40**, 358-360. <https://doi.org/10.1111/j.1479-828X.2000.tb03353.x>
- [9] Zhang, Z. and Yang, Q. (2023) Primary Diffuse Large B-Cell Tumor of the Uterus: A Case Report. *Frontiers in Medicine*, **10**, Article ID: 1234861. <https://doi.org/10.3389/fmed.2023.1234861>
- [10] Salem, U., Menias, C.O., Shaaban, A., *et al.* (2014) Hematopoietic Tumors of the Female Genital System: Imaging Features with Pathologic Correlation. *Abdominal Imaging*, **39**, 922-934. <https://doi.org/10.1007/s00261-014-0102-4>
- [11] Cubo, A.M., Soto, Z.M., Cruz, M.Á., *et al.* (2017) Primary Diffuse Large B Cell Lymphoma of the Uterine Cervix Successfully Treated by Combined Chemotherapy Alone. *Medicine*, **96**, e6846. <https://doi.org/10.1097/MD.0000000000006846>
- [12] Desana, B., Balbo Mussetto, A., Macera, A., *et al.* (2020) Rare Case of Uterine Cervix Lymphoma with Spontaneous Regression: Case Report. *Journal of Obstetrics and Gynaecology Research*, **47**, 807-811. <https://doi.org/10.1111/jog.14562>
- [13] Cheng, H., Tang, X., Cheng, J., *et al.* (2017) Pathologic Character and Diagnosis of Female Primary Genital System Diffuse Large B-Cell Lymphoma. *European Review for Medical and Pharmacological Sciences*, **21**, 1471-1476.
- [14] Tyagi, A., Abrari, A. and Mukherjee, U. (2021) Primary Diffuse Large B-Cell Lymphoma Masquerading as Uterine Fibroid: A Pathologistsf Diagnosis. *Journal of Cancer Research and Therapeutics*, **17**, 288-290. [https://doi.org/10.4103/jcrt.JCRT\\_499\\_18](https://doi.org/10.4103/jcrt.JCRT_499_18)
- [15] Goda, J.S., Gaikwad, U., Narayan, A., *et al.* (2020) Primary Diffuse Large B Cell Lymphoma of Uterine Cervix: Treatment Outcomes of a Rare Entity with Literature Review. *Cancer Reports*, **3**, e1264. <https://doi.org/10.1002/cnr2.1264>
- [16] 陈芳, 段华, 王克杨, 等. 原发性子宫大B细胞淋巴瘤一例报告及文献复习[J]. 现代生物医学进展, 2020, 120(19): 3683-3686.
- [17] Dorth, J.A., Prosnitz, L.R., Broadwater, G., *et al.* (2012) Radiotherapy Dose-Response Analysis for Diffuse Large

B-Cell Lymphoma with a Complete Response to Chemotherapy. *Radiation Oncology*, **7**, Article No. 100. <https://doi.org/10.1186/1748-717X-7-100>

- [18] Hilal, Z., Hartmann, F., Dogan, A., *et al.* (2016) Lymphoma of the Cervix: Case Report and Review of the Literature. *Anticancer Research*, **36**, 4931-4940. <https://doi.org/10.21873/anticancer.11059>
- [19] Del, M., Angeles, M.A., Syrykh, C., *et al.* (2020) Primary B-Cell Lymphoma of the Uterine Cervix Presenting with Right Ureter Hydronephrosis: A Case Report. *Gynecologic Oncology Reports*, **34**, Article ID: 100639. <https://doi.org/10.1016/j.gore.2020.100639>
- [20] Mohammed Saeed, D., Patel, P., Guzman, G., *et al.* (2020) A Case of Classic Hodgkin Lymphoma Involving the Uterine Cervix Presenting as Vaginal Spotting. *Cureus*, **12**, e8889. <https://doi.org/10.7759/cureus.8889>
- [21] Capsa, C., Calustian, L.A., Antoniu, S.A., *et al.* (2022) Primary Non-Hodgkin Uterine Lymphoma of the Cervix: A Literature Review. *Medicina*, **58**, Article 106. <https://doi.org/10.3390/medicina58010106>
- [22] Ahmad, A.K., Hui, P., Litkouhi, B., *et al.* (2014) Institutional Review of Primary Non-Hodgkin Lymphoma of the Female Genital Tract: A 33-Year Experience. *International Journal of Gynecologic Cancer*, **24**, 1250-1255. <https://doi.org/10.1097/IGC.0000000000000201>